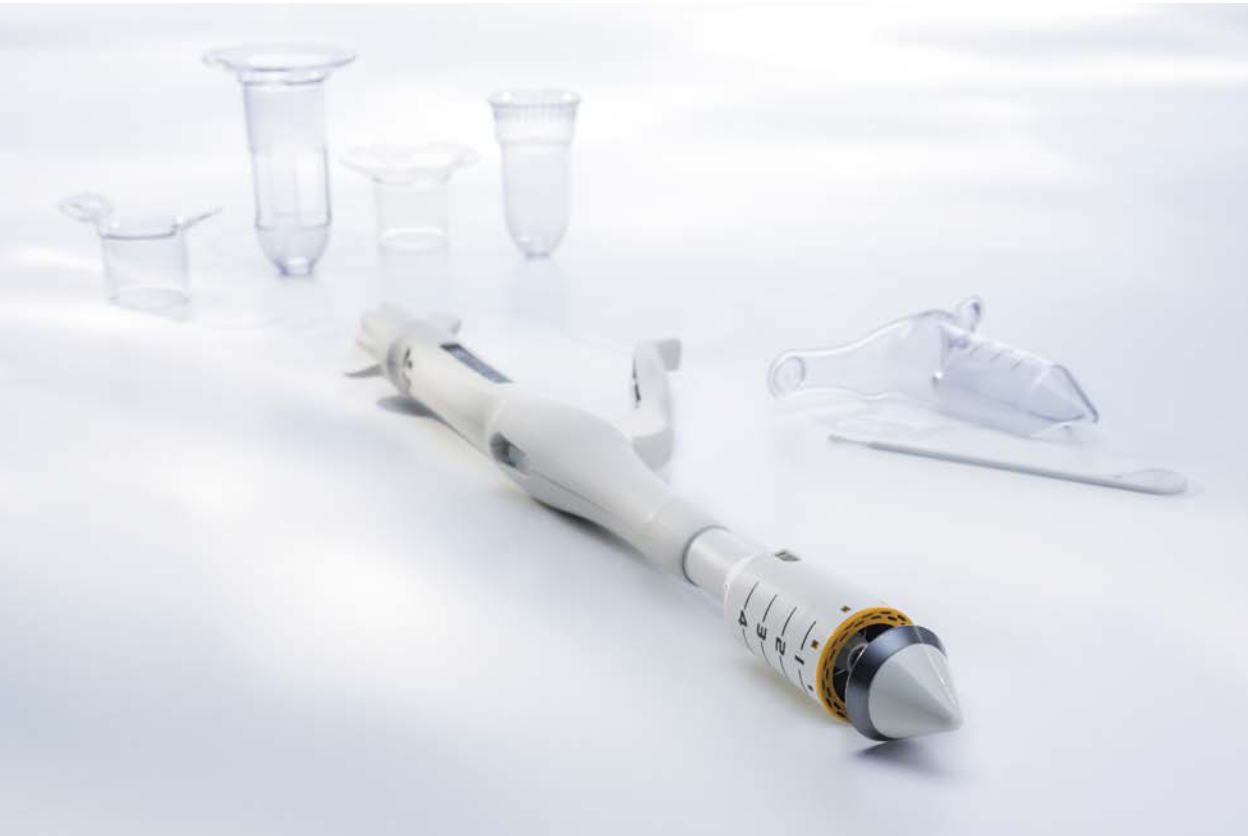



GENERAL  
OPEN SURGERY

# TST33 – TISSUE-SELECTING THERAPY STAPLER

SINGLE USE INTERNAL STAPLER

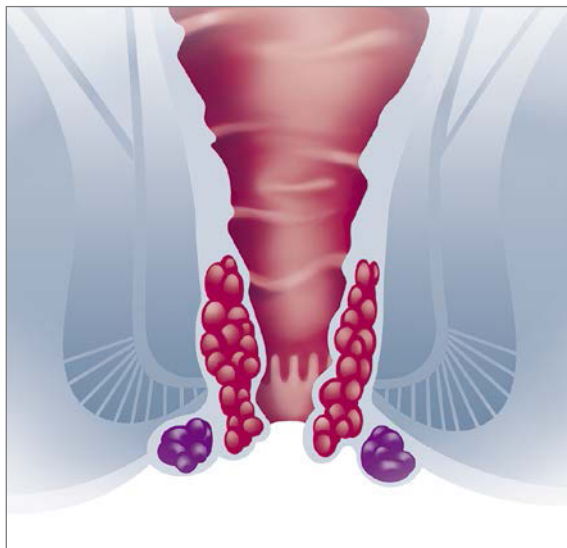
# TST33 – TISSUE-SELECTING THERAPY STAPLER

SINGLE USE INTERNAL STAPLER

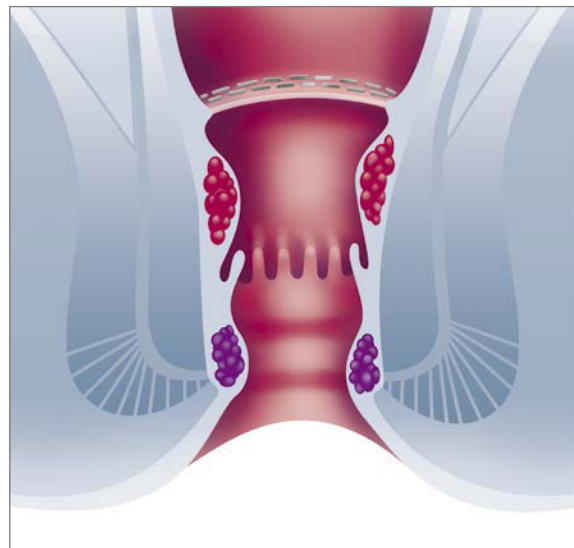
EXISTING CLINICAL PROBLEMS



- Circular Stapled Hemorrhoidopexy (CSH), characterized by a circular incision of the rectal mucosa<sup>1</sup>, is an effective technique for treating prolapsing hemorrhoids.
- However, the incidence of postoperative urgency and anal stenosis was reported to be as high as 40%<sup>2</sup> and 6%<sup>3</sup>, respectively.
- Removal of large areas of the anoderm and hemorrhoidal rectal mucosa, without the sparing of adequate mucocutaneous bridges, can lead to scarring and a progressive chronic stricture<sup>3,4</sup>.
- These complications, might be related to the presence of too many staples in the sensitive lower rectum and the nature of the staple line (full circumference)<sup>5</sup>.



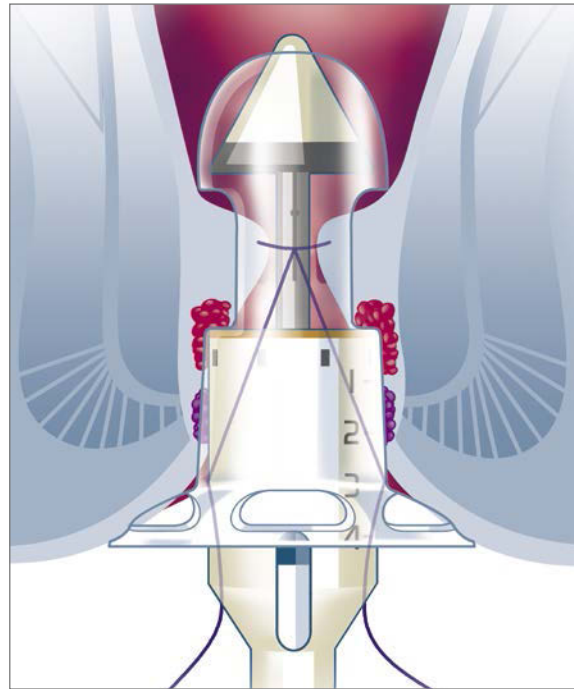
Before treatment



After treatment

## SELECTIVE CUT, LESS INVASIVE

- To overcome the limitations and weaknesses of CSH, Partial Stapled Hemorrhoidopexy (PSH) has been proposed as a new and effective less invasive technique<sup>5</sup>.
- PSH is characterized by the DAO unit, with one, two or three windows, with which the rectal mucosa above the prolapsing hemorrhoids is partially resected to spare the mucosal bridges between the mucosectomies.
- Due to removal of the target tissue and preservation of the normal tissue, PSH is also called Tissue-Selecting Therapy (TST).



Technique

### DAO UNITS – DILATOR ANOSCOPE OBTURATOR



One window

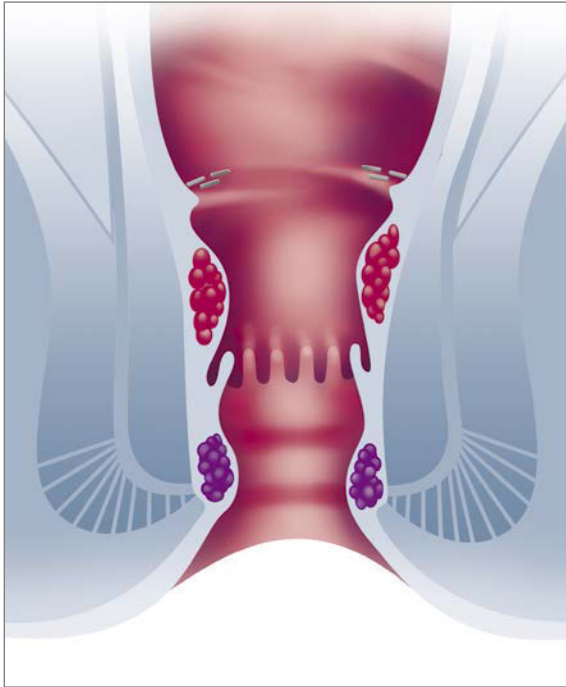


Two windows



Three windows

# CLINICAL BENEFITS



After TST treatment

In comparison to CSH, TST is associated with<sup>5</sup>:

- Less postoperative pain
- Fewer episodes of urgency
- No postoperative anal incontinence
- No anal stenosis

### Indication

- Grade II - IV hemorrhoids
- Partial hemorrhoids
- Circular hemorrhoids

## CLINICAL OUTCOMES OF TST VS PPH (PROCEDURE FOR PROLAPSE AND HEMORRHOIDS) TECHNIQUE<sup>5</sup>

Case No.	Post-Op Pain Score / 1 <sup>st</sup> Defecation	Post-Op Urgency / 7 Days	Gas Incontinence	Anal Stenosis / 2 Years
TST (34 cases)	2 (2-4)	11.8%	0%	0%
PPH (38 cases)	4 (2-6)	31.6%	7.9%	2.6%
P=Value	0.001	0.043	0.242	1.0

REFERENCES

- <sup>1</sup> Longo A. Treatment of hemorrhoidal disease by reduction of mucosa and hemorrhoidal prolapse with a circular suturing device: a new procedure. Proceedings of the 6th world Congress of endoscopic surgery. 1998;777-84.
- <sup>2</sup> Fueglistaler P, Guenin MO, Montali I. Long-term results after stapled hemorrhoidopexy: high patient satisfaction despite frequent postoperative symptoms. Dis Colon Rectum. 2007;50:204-12.
- <sup>3</sup> Brisinda G, Vanella S, Cadeddu F. Surgical treatment of anal stenosis. World J Gastroenterol. 2009;15:1921-8.
- <sup>4</sup> Brisinda G. How to treat haemorrhoids. Prevention is best; haemorrhoidectomy needs skilled operators. BMJ. 2000;321:582-3.
- <sup>5</sup> Lin HC, Ren DL, He QL, Peng H, Xie SK, Su D, et al. Partial stapled hemorrhoidopexy versus circular stapled hemorrhoidopexy for grade III-IV prolapsing hemorrhoids: a two-year prospective controlled study. Tech Coloproctol. 2012;16(5):337-43.

ORDER INFORMATION

Article No.	Titanium Staple Rows	Staple Quantity	Staple Height	Anvil Diameter	Close Staple Height	Staple Housing Volume
TST33-WS	2	32	4.0 mm	33 mm	0.75-1.5 mm	19 ml

Transanal Accessories



Manufacturer acc. to MDD 93/42/EEC

Touchstone International Medical Science Co., Ltd. | 21 A Science Plaza  
International Science Park | No. 1355 Jinjihu Avenue | Suzhou | China

Distributed by:

B. Braun Surgical, S.A. | Carretera de Terrassa, 121 | 08191 Rubí | Spain  
Phone +34 93 586 6200 | Fax +34 93 699 6330 | [www.bbraun.com](http://www.bbraun.com)

## AESCULAP<sup>®</sup> – a B. Braun brand

Aesculap AG | Am Aesculap-Platz | 78532 Tuttlingen | Germany  
Phone +49 7461 95-0 | Fax +49 7461 95-2600 | [www.aesculap.com](http://www.aesculap.com)